

# A Technique for Correction of Equinus Contracture Using a Wire Fixator and Elastic Tension

*J. Stuart Melvin, MD\* and Laurence E. Dahners, MD†*

**Summary:** Equinus contracture often is a complication of trauma, burns, or neurologic deficit. Many patients with contractures secondary to trauma or burns have poor soft tissue, which makes invasive correction a less appealing option. The Ilizarov external fixator has been used as a less invasive attempt to correct equinus contracture. We describe our “dynamic” technique and present a clinical patient series using a variation of the unconstrained Ilizarov technique, which uses elastic bands rather than threaded rods to supply the corrective force.

**Key Words:** equinus, Ilizarov, contracture, dorsiflexion, ankle

*(J Orthop Trauma 2006;20:138–142)*

Trauma, burns, neuromuscular disorders, limb lengthening, and other conditions can lead to equinus contractures of the ankle. Treatment has ranged from serial casting in milder cases to tendon lengthening, open tissue release, and even osteotomy in more severe cases. Many patients with contractures secondary to trauma or burns have poor soft tissue, which makes invasive correction a less appealing option. The Ilizarov external fixator, using distraction histogenesis, also has been used as a less invasive attempt to correct equinus contracture.<sup>1–5</sup>

Two variations of the Ilizarov method, constrained and unconstrained, have been described. The constrained method involves hinges, which define the axis of correction. Because the center of rotation of the ankle joint changes during ankle joint motion, frequent adjustments to the hinges are required to achieve ideal correction.<sup>6</sup> This method is technically cumbersome for the surgeon and burdensome for the patient.

The unconstrained method uses the ankle joint as a natural hinge to define the axis of motion. This method seems simpler, less invasive, and proceeds through a more physiologic motion.<sup>7</sup> Both of these methods use threaded rods connecting the tibial components to the forefoot and hindfoot

components. These are adjusted at a rate not  $>1$  mm per day to correct equinus.

Two variations of the unconstrained Ilizarov technique using elastic bands to dynamically connect the Ilizarov components rather than threaded rods have been used by the senior surgeon (LED) during the past 12 years. These methods are technically simple, require no participation by the patient to adjust rods and, because of the elasticity of the tubing, allow active range of motion during the correction period. We describe these two techniques and our clinical experience with an Ilizarov construct using elastic tubing for dynamic correction of equinus contracture.

## TECHNIQUE

### Construct Using Anterior Elastic Tubing

Two 5-mm external fixation half-pins are placed anteromedially in the middle third of the tibia through stab incisions aligned parallel to the tibial shaft (Figs. 1 and 2). A pin bank is used as a guide to space the pins 6 to 10 cm apart. The depth of the pins is confirmed with fluoroscopy. A pin bank is used to connect the half-pins in such a fashion that an attachment point is available directly anteriorly over the tibial crest. We frequently use the Rancho cubes from the Smith and Nephew Ilizarov instrument set as a pin bank and attach a second Rancho cube to it so that it extends laterally to the midline from the anteromedial pins.

Attention is then turned to placing the forefoot half-ring. A 1.8-mm “olive” wire is driven through the base of the fifth metatarsal and across the forefoot from lateral to medial so that it exits through the base of the first metatarsal. This leaves the “olive” as a stop against the lateral side of the fifth metatarsal. The position is confirmed with fluoroscopy. A half-ring (we again use the Ilizarov rings) is attached dorsally across the forefoot and is tensioned to 90 kg. A 3/4-inch Penrose drain is then threaded through a hole of the tibial pin bank at the midline and through a hole in the Ilizarov half-ring in a position that applies a dorsiflexion force that maintains neutral subtalar alignment. The Penrose drain is then stretched substantially to apply a dorsiflexion force and tied to itself.

### Construct Using Anterior and Posterior Elastic Tubing

We begin by placing a proximal tibial ring. Two 5-mm half-pins are placed anteromedially through stab incisions into the middle third of the tibia using a 4-hole Rancho cube as a guide (Fig. 3). The depth of the pins is confirmed with fluoroscopy. The half-pins are secured to the 4-hole Rancho

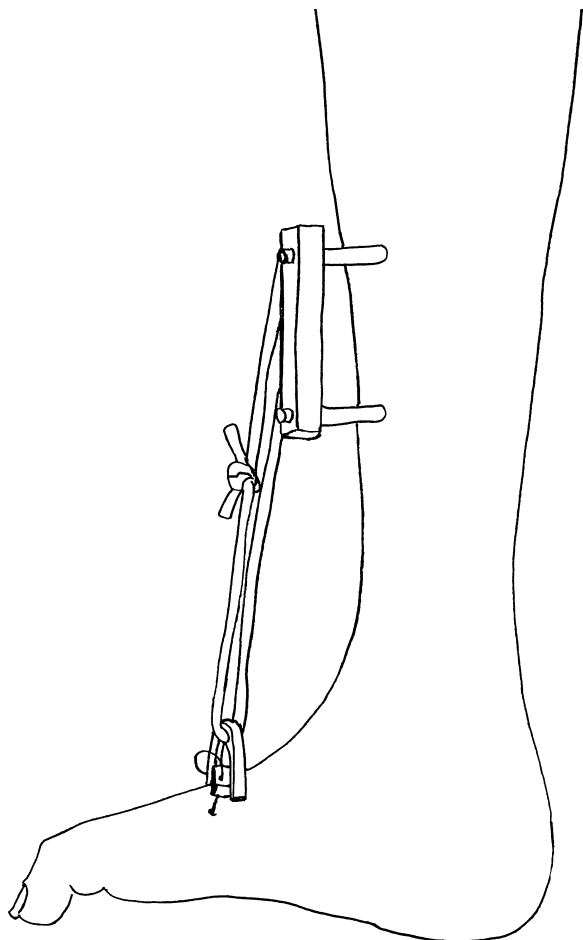
Accepted for publication August 8, 2005.

From the Department of Orthopaedic Surgery, University of Pennsylvania, Philadelphia, PA; and the †Department of Orthopaedic Surgery, University of North Carolina at Chapel Hill, Chapel Hill, NC.

Supported by J. Stuart Melvin Short Term Research Training Program Grant funded by a grant from the National Institution for Diabetes and Digestive and Kidney Diseases.

Reprints: Laurence Dahners, MD, Department of Orthopaedics CB #7055, Bioinformatics Building, UNC School of Medicine, Chapel Hill, NC 27599-7055 (e-mail: laury@med.unc.edu).

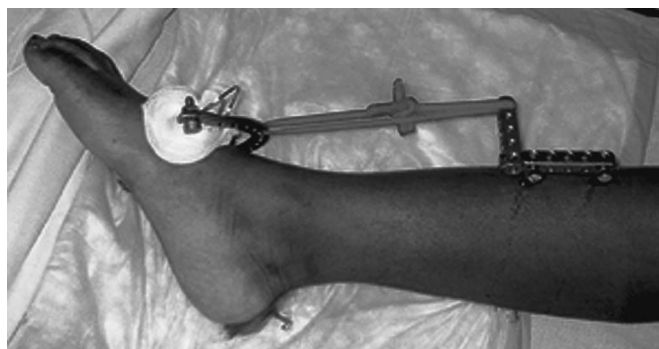Copyright © 2006 by Lippincott Williams & Wilkins



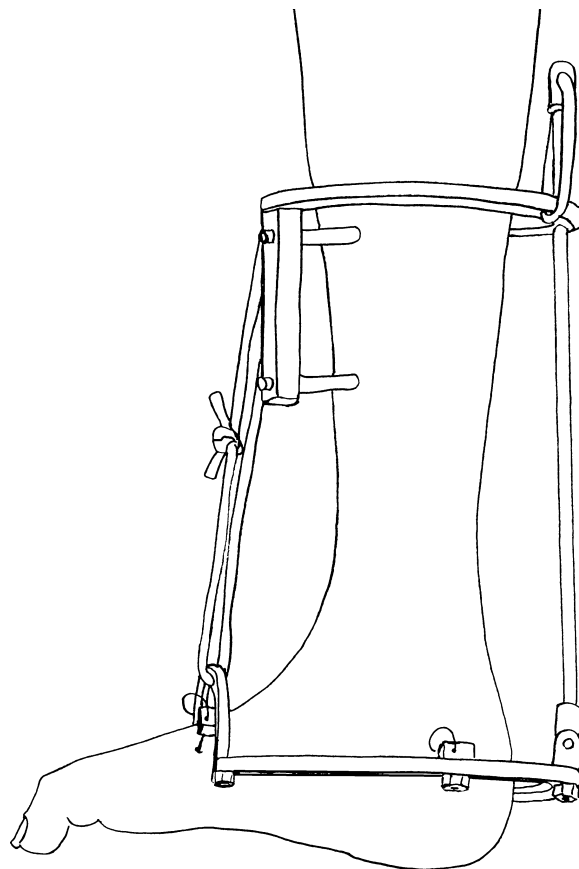
**FIGURE 1.** Ilizarov construct using anterior elastic tubing to provide corrective force.

cube and a circular Ilizarov ring large enough to allow 2-cm clearance circumferentially about the leg is attached to the Rancho cube.

Attention is then turned to the distal construct. An appropriately sized distal oval ring consisting of 2 half-rings and 2 plates is constructed from Ilizarov components. The distal half-ring arches over the foot dorsally and the posterior ring passes posterior to the calcaneus in the axial plane (the



**FIGURE 2.** Clinical photograph depicting construct using anterior elastic tubing.



**FIGURE 3.** Ilizarov construct using anterior and posterior elastic tubing to provide corrective force.

dorsal ring is 90 degrees to the axial ring) with the plates spanning the distance between them. A 1.8-mm olive wire is positioned through the bases of the fifth and first metatarsal (as above in the first technique) and attached to the dorsal foot ring. Another wire is placed through the posterior tuberosity of the calcaneus, this time placing the olive on the medial side. The wires are tensioned to 90 kg.

To dynamically link the foot and tibial constructs, a threaded rod is then placed through the posterior aspect of the tibial ring extending distally to attach to the posterior foot ring with a hinge. The proximal end of the rod extends through a hole in the ring and approximately 5 to 10 cm proximal to the ring. A 3/4-inch Penrose drain is then stretched and tied to the proximal end of the rod and to the tibial ring to apply a compressive force pushing the threaded rod and the posterior aspect of the oval ring distally to force the heel inferiorly. Next, a 3/4-inch Penrose drain is threaded through a hole of the tibial ring anteriorly at the midline and through a hole in the distal oval ring that arches dorsally over the forefoot in a position that allows for neutral subtalar alignment. The Penrose drain is then stretched substantially to apply a dorsiflexion force and tied to itself.

### Postoperative Management

The elastic tension is increased or decreased at follow-up appointments based on patient comfort and degree of

correction. The Penrose tubing can be changed to thicker, more durable Thera-band tubing (The Hygenic Corporation, Akron, OH) to provide increased tension as needed at follow-up appointments. The patient is instructed to actively dorsiflex and plantarflex the ankle several times daily, whereas the constant dynamic dorsiflexion force gradually brings them up out of equinus. The device is generally removed when the patient stops making progress toward dorsiflexion or the patient has maintained neutral or greater dorsiflexion for 2 to 3 weeks. After removal of the device, patients can be placed in a short leg cast, or a fracture walker boot; however, many of our patients were not further immobilized when their ankle seemed supple and our clinical judgment was that the likelihood that the ankle would revert to equinus was low.

### CLINICAL SUMMARY

This technique was used on 20 patients (22 ankles) during a 12-year period (Table 1). After obtaining institutional review board-approval, these patients were identified and we were able to contact 13 patients (13 ankles) for follow-up measurement of ankle motion. One patient (1 ankle) was lost to follow-up after undergoing tibiotalar osteotomy and arthrodesis to achieve a plantigrade ankle, because he failed to achieve correction with this technique. This patient was included in this summary because his tibiotalar arthrodesis was considered a definitive end point of treatment.

Equinus was secondary to trauma in 7, trauma with peroneal nerve deficit in 1, trauma with peroneal deficit, and central nervous system (CNS) deficit with spasticity in 1, burn in 4, and bone transport in 1. No patient had had previous surgical treatment of his or her equinus contracture.

Preoperative and during-correction measurements of equinus were clinical estimations gathered from clinic notes, whereas the final dorsiflexion measurement was made with precision using an elongated goniometer as described by Rome.<sup>8</sup>

The mean follow-up period was 49 (range, 3–150) months. All but 1 patient achieved 0° dorsiflexion or greater while in the Ilizarov apparatus. This patient's contracture was the result of a severe lower extremity burn 6 years before the procedure. He had undergone no previous treatment and had the largest preoperative contracture (70°) in our series. He was the patient described above who eventually required tibiotalar arthrodesis to attain a plantigrade foot. Overall, the mean initial correction was a 35° increase in dorsiflexion, whereas the mean correction at final follow-up was a 33° increase in dorsiflexion for the 11 patients who underwent no subsequent equinus corrective procedure and a 42° increase in the 2 who did.

Nine of the 14 patients maintained >0° dorsiflexion, whereas 5 patients did not. Of these 5 patients, 1 achieved maintenance of >0° dorsiflexion with tendoachilles lengthening (TAL). A second achieved maintenance of >0° dorsiflexion after 2 TAL procedures, 2 flexor hallucis longus releases (FHL), 1 flexor digitorum longus release (FDL), and 1 tibiotalar capsulotomy. A third patient achieved a neutral ankle via arthrodesis. The remaining 2 patients chose to accept their improved but persistent equinus contracture.

The etiology of contracture for patients maintaining >0° dorsiflexion was trauma in 7 patients, trauma with peroneal nerve deficit in 1, and bone transport in 1. The etiology of contracture for patients unable to maintain DF >0° was burn in 4 and trauma with peroneal nerve and CNS deficit with spasticity in 1. The results for these groups are summarized in Table 2.

Post-Ilizarov immobilization for those maintaining >0° dorsiflexion consisted of short leg cast in 1, AFO in 2, fracture walker boot in 2, and no immobilization in 4. For those unable to maintain correction at final follow-up, postprocedure immobilization consisted of short leg cast in 4 and fracture walker boot in 1.

Complications included claw toes in 4, requiring release in 3. One patient noted severe pain while in the apparatus, which was relieved by loosening the dorsiflexion tension. Three patients were noted to drift into valgus while the Ilizarov apparatus was in place. This was corrected by adjusting the proximal attachment of the tubing to provide a varus force. Pin site infections developed in 3 and were treated adequately with cephalixin. No joint subluxation was noted clinically.

### DISCUSSION

We have reported our experience with a variation of the unconstrained Ilizarov method using elastic tubing rather than threaded rods for treatment of equinus contracture. Compared with threaded rods, this method is technically simpler, allows range of motion while in the apparatus, and requires minimal participation on the patient's behalf (they do not have to adjust their device daily as when threaded rods are used). Adjustments to the position and tension of the tubing are made at regular follow-up appointments.

This technique also offers advantages over more conventional equinus corrective procedures, such as serial casting or TAL. Poor soft-tissue conditions for a number of patients in this series, RSD for 1 patient and the ability to allow joint motion during the correction period, were considerations that made this technique a more appealing alternative.

The corrective force provided by the elastic tubing was sufficient to achieve neutral or greater dorsiflexion for all but 1 of the equinus contractures in our series. Only the patient with the largest preoperative contracture of the longest duration was unable to achieve initial dorsiflexion of neutral or greater while in the apparatus. More invasive techniques, such as that used by Hahn et al,<sup>9</sup> which involved scar excision, free tissue transfer, open TAL in addition to an Ilizarov construct, may be required for a successful outcome in these patients with significant scar and large contractures.

Lengthening the corrective period through postapparatus casting or bracing did not affect maintenance of correction. Those unable to maintain correction all had a period of rigid immobilization with short leg cast or walker boot. Of those maintaining correction, only 5 of 9 patients had a post-Ilizarov period of rigid immobilization. This suggests that factors, such as etiology or duration of contracture rather than duration of corrective force, affected whether this procedure was able to provide lasting correction.

**TABLE 1.** Clinical Data for All Patients

Patient	Age (yr)	Duration Of Equinus	Days in Ilizarov	Etiology	Construct Type	Post- Ilizarov Immobilization
Maintained Correction						
1	27	<1 yr	28	Trauma	Ant/Post	SLC Boot
2	44	7 mo	44	Peroneal injury	Ant	AFO
3	45	<1 yr	33	Trauma	Ant	None
4	47	1 yr	36	Trauma	Ant	AFO
5	20	<1 yr	41	Trauma	Ant/Post	None
6	49	<1 yr	32	Trauma	Ant	None
7	42	3 mo	27	Limb lengthening	Ant	Boot
8	42	<1 yr	89	Trauma degloving	Ant	Boot
9	28	15 mo	74	Trauma	Ant	None
Unable to maintain correction						
10	21	>1 yr	41	Burn	Ant/Post	SLC Boot
11	45	72 mo	43	Burn	Ant/Post	Boot
12	36	27 mo	39	Burn	Ant/Post	SLC
13	42	<1 yr	21	Burn	Ant/Post	SLC Boot
14	42	>1 yr	70	Trauma peroneal injury	Ant	SLC Boot

Patient	Complication	Subsequent Procedures	Estimated Preoperative Equinus	DF in Ilizarov	Final DF	Final DF Unaffected Limb
Maintained Correction						
1	Claw toe	FDL release	-45	+10	+10	+37
2	None	None	-25	+5	+23	+29
3	Severe Pain	None	-10	+20	+18	+35
4	None	None	-8	???	+9	+25
5	None	None	-10	+5	+12	+24
6	Pin site Infection	None	???	+20	+22	+31
7	Valgus	None	-30	+5	+5	+29
8	Valgus, Claw toe	FDL release	-30	0	+5	+15
9	Valgus	None	-20	+15	+18	+34
Unable to maintain correction						
10	Claw toe	TAL x 2, FHL x 2, Capsulotomy, FDL x 1	-40	0	+6	+15
11	Pin site infection	Ankle arthrodesis	-70	???	???	???
12	None	None	-20	+10	-5	+19
13	Pin site infection	None	-60	0	-15	+28
14	Claw toe	TAL	-15	+15	+23	+34

DF, dorsiflexion; SLC, Short Leg Cast.

Our series does demonstrate clear distinctions between those patients able to maintain neutral or greater dorsiflexion and those unable to maintain it. It seems that a burn etiology of contracture, a long duration of contracture, and a large contracture before surgery correlated with inability to maintain correction. Of these, etiology of contracture may be the most important, because the contrast of outcomes between trauma patients and burn patients are distinct. It is unclear why burn contractures tended to revert to equinus. It could be conjectured that burn contractures have a greater propensity to recur because of ongoing scar contracture. This seems unlikely in our series given that 3 of the 4 burn contractures were treated more than 1 year after the contracture formed when the scar was likely stable. Unfortunately, burn patients

would seem to have the most to gain from a less invasive equinus correction procedure because of compromised skin and soft-tissue envelopes in which serial casting, osteotomy, or tendoachilles lengthening would be risky alternatives. Despite being unable to maintain neutral or better dorsiflexion, 2 of 4 burn patients experienced large improvements in their contractures and elected not to pursue further treatment. Thus, this technique may lead to improved function by decreasing the degree of deformity without necessarily maintaining a plantigrade foot and therefore may remain a useful alternative to more invasive procedures.

It is unclear how effective this technique is for those with neurologic deficits. One patient with common peroneal deficit secondary to trauma maintained greater than neutral

**TABLE 2.** Comparison of Outcome Groups

	Maintained DF >0° (9 patients)	Unable to Maintain DF >0° (5 patients)
Mean (range) age at operation (yr)	38 (20–49)	37 (21–45)
Percentage with equinus <1-yr duration	89%	20%
Mean (range) time in Ilizarov External Fixator (days)	45 (27–89)	43 (21–70)
Percentage of Ilizarov constructs utilizing hindfoot distraction	22%	80%
Mean (range) preoperative contracture (degrees from neutral)	–22 (–8 to –45)	–41 (–15 to –70)
Mean (range) Dorsiflexion in Ilizarov External Fixator (degrees from neutral)	+11 (0–20)	+6 (0–15)
Mean (range) overall initial correction (degrees of correction)	32 (15–65)	40 (30–60)
Mean (range) dorsiflexion at study follow-up (degrees from neutral)	+14 (5–23)	+2 (–15–23)
Mean (range) overall final correction (degrees of correction)	33 (17–55)	36 (15–46)
Mean (range) dorsiflexion of uninvolved side (degrees from neutral)	+29 (15–37)	+24 (15–34)

dorsiflexion, whereas a second patient with common peroneal deficit secondary to trauma, but complicated by a CNS deficit and spasticity, was unable to maintain correction without TAL. This technique may not be as effective for patients with dynamic muscle imbalance as the technique does not address the underlying pathology. Contractures with a CNS component and spasticity have been successfully treated non-operatively with physiotherapy, serial casting, and in some cases the addition of botulism toxin.<sup>10</sup> Perhaps for these patients refractory to physiotherapy, this technique, with or without the addition of botulism toxin, may be an alternative to serial casting with the advantage of allowing active joint motion during treatment.

This technique seems best suited for contractures of a traumatic etiology. All patients in our series with contractures secondary to trauma maintained dorsiflexion >0° at final follow-up. Huang,<sup>3</sup> using a hinged Ilizarov construct, also noted better results for those with contractures secondary to trauma. The improved soft-tissue conditions and shorter duration of contracture likely contributed to the improved outcome in these patients.

Consideration should be given to potential complications when considering treatment options. The most common complications in our series were partial recurrence of the contracture and clawtoe. Clawtoe results because the toes are not constrained by the device and thus their tendons are not stretched. We corrected this with flexor tenotomy. However, there have been reports of preventing clawtoe with prophylactic percutaneous pinning across the distal interphalangeal, proximal interphalangeal, and metatarsophalangeal joints or

using elastic tubing around the toes and attached proximally to the external fixator.<sup>11,12</sup>

## REFERENCES

1. Calhoun JH, Evans EB, Herndon DN. Techniques for the management of burn contracture with the Ilizarov fixator. *Clin Orthop*. 1991;280:117–124.
2. Grant AD, Atar D, Lehman WB. The Ilizarov technique in correction of complex foot deformities. *Clin Orthop*. 1992;280:94–103.
3. Huang S-C. Soft tissue contracture of the knee or ankle treated by Ilizarov technique: high recurrence rate in 26 patients followed for 3–6 years. *Acta Orthop Scand*. 1996;67:443–449.
4. Oganessian OV, Istomina IS. Talipes equinovarus deformities corrected with the aid of hinged distraction apparatus. *Clin Orthop*. 1991;266:42–50.
5. Oganessian OV, Istomina IS, Kuzmin VI. Treatment of equinovarus deformity in adults with the use of a hinged distraction apparatus. *J Bone Joint Surg Am*. 1996;78:546–556.
6. Sammarco GJ, Burstein AH, Frankel VH. Biomechanics of the ankle: a kinematic study. *Orthop Clin North Am*. 1973;4:75–96.
7. Tsuchiya H, Sakurakichi K, Uehara K, et al. Gradual closed correction of equinus contracture using the Ilizarov apparatus. *J Orthop Sci*. 2003;8:802–806.
8. Rome K. Ankle joint dorsiflexion measurement studies: a review of the literature. *J Am Podiatr Med Assoc*. 1996;86:205–210.
9. Hahn SB, Hong JP, Park HW, et al. Treatment of severe equinus deformity associated with extensive scarring of the leg. *Clin Orthop Relat Res*. 2001;393:250–257.
10. Singer BJ, Dunne JW, Singer KP, et al. Non-surgical management of ankle contracture following acquired brain injury. *Disabil Rehabil*. 2004;26:335–345.
11. Wallander H, Hansson G, Tjernstrom B. Correction of persistent clubfoot deformities with the Ilizarov external fixator. *Acta Orthop Scand*. 1996;67:283–287.
12. Kocaoglu M, Eralp L, Atalar AC, et al. Correction of complex foot deformities using the Ilizarov external fixator. *J Foot Ankle Surg*. 2002;41:30–39.