

An Analysis of the Demographic and Technical Characteristics Associated with Iliac Cortical Perforation During Insertion of Iliosacral Screws

¹J. Stuart Melvin, MD

²Nicholas Pulos, MD

³Keith Baldwin, MD, MPH, MSPT

³Amer Mirza, MD

³Michael J. Gardner, MD

³Samir Mehta, MD

¹OrthoCarolina, Charlotte, NC, USA

²Department of Orthopaedic Surgery,
University of Pennsylvania,
Philadelphia, PA

³Department of Orthopaedic Surgery,
Oregon Health & Science University,
Portland, OR

³Department of Orthopaedic Surgery,
Washington University, St. Louis, MO

Introduction

After initial resuscitation and stabilization, anatomic reduction of the pelvic ring with stable fixation leads to earlier patient mobility, decreased pain and improved outcomes.¹⁻⁴ Iliosacral screws have become the standard for fixation of most injuries to the posterior pelvic ring and have generally been associated with limited blood loss as well as low rates of infection and nonunion.⁵⁻¹⁰ Reports of complications for iliosacral screws have focused on nerve and vessel injury.^{5,11-15} Perforation of the outer cortex of the ilium during the final tightening of iliosacral screws has long been observed but seldomly reported. This complication may compromise the fixation of pelvic ring injuries. The aim of this study was to identify risk factors associated with breach of the outer iliac cortex during iliosacral screw insertion.

Methods

One hundred and forty-two consecutive patients who had undergone iliosacral screw fixation of the posterior pelvic ring from July 2006 to June 2010 and had post-operative CT scans were retrospectively identified from three Level 1 trauma centers. Charts were reviewed for potential epidemiologic risk factors such as age, time from injury to surgery, smoking status, and diagnosis of diabetes. All pelvic radiographs and CT scans were reviewed for number of screws, laterality of screws, screw thread length (partial vs. fully threaded) and for intrusion of the screw and washer through the outer iliac cortex. Injury patterns were classified according to the OTA classification.

Results

Two hundred and thirty-six iliosacral screws with washers were inserted for an average of 1.66 screws per patient. Twenty-eight screws (11.8%) in 26 patients (18.3%) perforated the outer cortex of the ilium (Figure 1A-B). Patients with screw perforation were significantly older (52.61 years vs. 38.6 years; $p=0.0002$) and were more likely to be diabetic ($p=0.0071$). Additionally, perforated screws were more often fully threaded ($p=0.0315$), and patients with a

perforated cortex had significantly more screws inserted (1.92 vs. 1.60; $p=0.037$). Cortical perforation on univariate analysis was not influenced in our series by gender ($p=0.40$), time to surgical fixation ($p=0.30$), laterality ($p=0.45$), smoking status ($p=0.99$), OTA Classification ($p=0.932$) or attending surgeon ($p=0.206$).

Discussion

Percutaneous iliosacral screw fixation of unstable pelvic ring injuries has become standard. This study demonstrates that perforation of the outer iliac cortex is relatively common during insertion of iliosacral screws and is associated with additional screws being inserted. Factors that may predispose to poor bone quality, such as age and diabetes, are associated with increased rates of cortical perforation. These factors should be kept in mind when performing final tightening of iliosacral screws. Interestingly, fully threaded screws were found to be significantly more likely to breach the iliac cortex compared

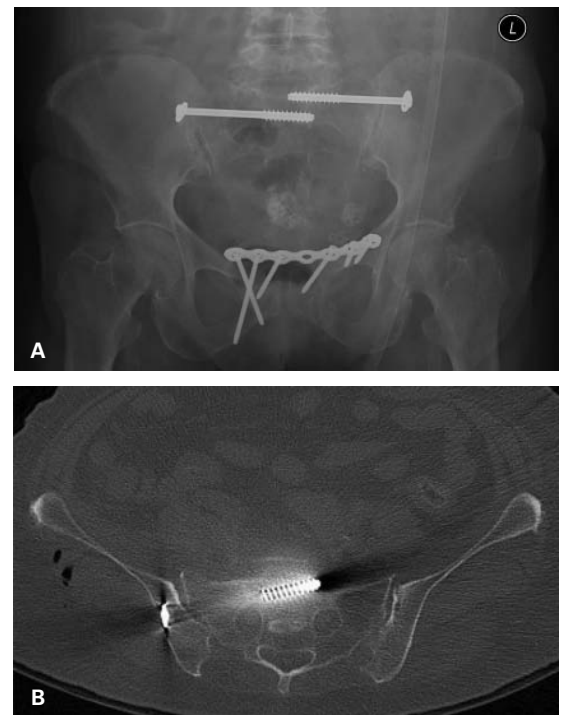


Figure 1. (A) AP pelvis demonstrating screw with intact iliac cortex on left and breach of iliac cortex by screw and washer on right. (B) Axial CT image depicting breach of the right iliac cortex by screw and washer.

Corresponding author:

J. Stuart Melvin, MD
OrthoCarolina
354 Copperfield Blvd.
Concord, NC 28025
Stu.melvin@gmail.com

to partially threaded screws. Further research is warranted to evaluate the effect of cortical perforation on reduction, healing and outcomes.

References

1. **Roult ML Jr, Nork SE, Mills WJ.** Percutaneous fixation of pelvic ring disruptions. *Clin Orthop* 2000;375:15-29.
2. **Goldstein A, Phillips T, Sclafani S, et al.** Early open reduction and internal fixation of the disrupted pelvic ring. *J Trauma* 1986;26:325-33.
3. **Matta J, Saucedo T.** Internal fixation of pelvic ring fractures. *Clin Orthop* 1989;242:83-7.
4. **Shuler TE, Boone DC, Gruen GS, et al.** Percutaneous iliosacral screw fixation early treatment for unstable posterior pelvic ring disruptions. *J Trauma* 1995;38:453-8.
5. **Roult ML Jr, Kregor PJ, Simonian PT, et al.** Early results of percutaneous iliosacral screws placed with the patient in the supine position. *J Orthop Trauma* 1995;9:207-14.
6. **Yinger K, Scalise J, Olson SA, et al.** Biomechanical Comparison of Posterior Pelvic Ring Fixation. *J Orthop Trauma* 2003;7:481-487.
7. **Keating JF, Werier J, Blachut P, et al.** Early fixation of the vertically unstable pelvis: the role of iliosacral screw fixation of the posterior lesion. *J Orthop Trauma* 1999;13:107-13.
8. **Moed BR, Geer BL.** S2 iliosacral screw fixation for disruptions of the posterior pelvic ring: a report of 49 cases. *J Orthop Trauma* 2006;20:378-83.
9. **Nork SE, Jones CB, Harding SP, et al.** Percutaneous stabilization of U-shaped sacral fractures using iliosacral screws: technique and early results. *J Orthop Trauma* 2001;15:238-46.
10. **Roult ML Jr, Simonian PT.** Closed reduction and percutaneous skeletal fixation of sacral fractures. *Clin Orthop* 1996;329:121-8.
11. **Roult ML Jr, Simonian PT, Mills WJ.** Iliosacral screw fixation: early complications of percutaneous technique. *J Orthop Trauma* 1997;11:584-9.
12. **Altman DT, Jones CB, Roult ML Jr.** Superior gluteal artery injury during iliosacral screw placement. *J Orthop Trauma* 1999;13:220-7.
13. **Sagi HC, Lindvall EM.** Inadvertent Intraforaminal Iliosacral Screw Placement Despite Apparent Appropriate Positioning on Intraoperative Fluoroscopy. *J Orthop Trauma*. 2005;19:130-133.
14. **Collinge C, Coons D, Aschenbrenner J.** Risks to the Superior Gluteal Neurovascular Bundle During Percutaneous Iliosacral Screw Insertion. *J Orthop Trauma*. 2005;19:96-101.
15. **Templeman D, Schmidt A, Freese J, et al.** Proximity of iliosacral screws to neurovascular structures after internal fixation. *Clin Orthop* 1996;329:194-8.